EJFA Emirates Journal of Food and Agriculture

Emirates Journal of Food and Agriculture 38: 1–8
doi: 10.3897/ejfa.2026.165582

RESEARCH PAPER FEEDING THE FUTURE

Transrectal ultrasonography of follicular dynamics and early pregnancy in mares: an on-site visual reference*

Juan Alberto Quintero-Elisea[1], José Vicente Velázquez-Morales[2,3], Hector Armando Olguin-Arredondo[4], Omar Francisco Prado-Rebolledo[5], Arturo César García-Casillas[5], Juan Augusto Hernández-Rivera[5]

1 *Universidad Autónoma de Tamaulipas, Unidad Académica Multidisciplinaria Mante, 89840 Cd. Mante, Tamaulipas, Mexico*
2 *Universidad Autónoma Metropolitana, Departamento de Biología de la Reproducción, 09340 Iztapalapa, Cd. México, Mexico*
3 *Instituto Mexicano del Seguro Social, Órgano de Operación Administrativa Desconcentrado, Hospital General de Zona No. 57, 54769 Cuautitlán, Edo. México, Mexico*
4 *Universidad Autónoma de Ciudad Juárez, Departamento de Ciencias Veterinarias, Instituto de Ciencias Biomédicas, 32310 Cd. Juárez, Chihuahua, Mexico*
5 *Universidad de Colima, Facultad de Medicina Veterinaria y Zootecnia, 28930 Tecomán, Colima, Mexico*

Corresponding author: Juan Augusto Hernández-Rivera (jhernandez2@ucol.mx)

Academic editor: Zeynep Ünal ♦ **Received** 18 July 2025 ♦ **Accepted** 3 December 2025 ♦ **Published** 23 January 2026

Abstract

This study aimed to characterize ovarian follicular dynamics and to describe the ultrasonographic features of early to after-gestation in mares under extensive field conditions. A total of 100 clinically healthy Spanish-type mares, averaging 8 ± 0.7 years of age and 500 ± 50 kg in body weight, were monitored over a 730-day period in three rural locations in Tamaulipas, Mexico. Transrectal ultrasonography was performed daily across a full estrous cycle (~21 days) to assess follicular development in non-pregnant mares. For mares confirmed pregnant 15 days post-mating, five ultrasound evaluations were conducted between days 15 and 150 of gestation. A total of 500 follicular and 500 gestational ultrasonographic images were obtained. Follicles were classified into three groups by diameter: 8–20 mm (n = 250; 50.0%), 21–30 mm (n = 150; 30.0%), and 32–45 mm (n = 100; 20.0%), with mean diameters of 13.7 mm, 25.4 mm, and 39.7 mm, respectively. The mean number of follicles per mare was 5.0, reflecting typical follicular activity during one estrous cycle under tropical field conditions. Gestational scans were distributed as follows: days 15–28 (n = 167; 33.4%; mean age: 21.9 d), days 30–45 (n = 166; 33.2%; mean age: 38.8 d), and days 50–150 (n = 167; 33.4%; mean age: 75.1 d). Key gestational features, such as the embryonic vesicle, heartbeat, and fetal skeleton, were documented per stage. In conclusion, structured ultrasonographic benchmarks for assessing follicular and gestational stages in mares were provided, offering practical tools for reproductive monitoring in field conditions.

Keywords

Early pregnancy, Follicular development, Mare reproduction, on-site diagnostics, Transrectal ultrasonography

* Topical Collection "Feeding the Future: Advancements in Deep Learning for Sustainable Agriculture and Food Security", edited by Prof. Yonis Gulzar & Zeynep Ünal.

Copyright *Quintero-Elisea, et al.* This is an open access article distributed under the terms of the Creative Commons Attribution License (CC-BY 4.0), which permits unrestricted use, distribution, and reproduction in any medium, provided the original author and source are credited.

Introduction

Reproductive efficiency in mares depends largely on the accurate identification of ovarian and uterine structures, which are directly associated with the timing of ovulation, conception, and early gestation (Benammar et al. 2021). Among available diagnostic techniques, transrectal ultrasonography (USG) has become the standard method for assessing follicular dynamics, ovulation, and early pregnancy (Renaudin et al. 1997; Squires et al. 2020). However, despite its routine use, the availability of detailed visual references representing normal reproductive stages under field conditions remains limited. This study hypothesizes that documenting follicular and early gestational features in mares under real management conditions can provide reliable, field-relevant ultrasonographic benchmarks for reproductive assessment. Previous studies have extensively described ovarian and uterine changes in mares during the oestrus cycle and early pregnancy (Squires et al. 2020). Most of these investigations, however, were conducted under controlled experimental conditions or with specialized equipment, limiting their applicability to field situations where environmental and management variability can affect reproductive performance (Cabeza and Gambini 2023). In practice, veterinarians working under extensive or semi-extensive systems face challenges such as inconsistent estrus detection, inadequate record-keeping, and variable operator expertise, which together hinder reproductive efficiency and diagnosis reliability. This limitation underscores the need for practical, field-relevant references that can guide routine veterinary practice. The increasing demand for accessible reproductive tools—especially in resource-limited settings—has prompted calls for the development of simple, image-based references to support oestrus monitoring and gestational evaluation (Lowe et al. 2020). These references serve not only as diagnostic guides but also as educational instruments for veterinary students, technicians, and breeders. The growing adoption of portable ultrasound technology has further reinforced the value of standardized image-based references in daily reproductive management (Ortega-Ferrusola et al. 2022; Lange-Consiglio et al. 2023). In recent reviews of reproductive strategies in mares, researchers have emphasized the importance of combining technological advances with applied methodologies to ensure broader accessibility and reproducibility of results (Cabeza and Gambini 2023; Khan et al. 2025). Additionally, studies involving assisted reproductive technologies in equine species highlight how improved visual diagnostics directly impact fertility outcomes and decision-making timelines (Benammar et al. 2021). As such, visual standards derived from ultrasonographic images are increasingly recognized as essential components of reproductive success, especially during early gestation when embryonic development is rapid and diagnostically sensitive. Unlike previous studies conducted under controlled experimental settings, this work provides real-world visual benchmarks derived from field conditions, enhancing the practical relevance of ultrasonographic assessment in mares. By addressing this need, the present study contributes with improving reproductive management by documenting follicular development during the oestrus cycle and describing the typical ultrasonographic appearance of the embryonic vesicle and/or fetus at sequential stages of early gestation. This aligns with recent efforts to enhance field diagnostics using practical and visual methodologies that are both accessible and applicable across diverse production systems (Benammar et al. 2021; Panzani et al. 2024). Finally, transrectal USG is expected to enable accurate characterization of follicular and gestational progression in mares under extensive management, generating a visual reference framework applicable in the field. Therefore, the objective of this study was to characterize ovarian follicular dynamics and visually describe the typical ultrasonographic features of early gestation (from days 15 to 150) in mares using transrectal USG, with the purpose of providing practical reference benchmarks for reproductive assessment.

Materials and methods

Location of the study

The study was conducted across three rural sites within the Temporalera region of El Mante municipality, Tamaulipas, Mexico: División del Norte (22°23'47"N, 98°52'21"W), Los Generales (22°23'38"N, 98°49'35"W), and Lázaro Cárdenas (22°23'28"N, 98°46'03"W). The area is characterized by a warm subhumid climate, with mean temperatures ranging from 22.7 °C to 24.2 °C, an average annual rainfall of approximately 160 mm, and relative humidity around 79%. The elevation of the study sites averages 90 m above sea level (INEGI 2025).

Experimental animals, and diet

The study extended over approximately 730 days, from June 2021 to August 2023. A total of 100 Spanish-type mares with comparable characteristics (mean age: 8 ± 0.7 years; body weight: 500 ± 50 kg) were evaluated through transrectal USG to monitor their reproductive activity throughout the experimental period. No mares showing signs of ovarian or uterine abnormalities were used. One-third of the mares were in one place (División del Norte), the second (Los Generales) and third (Lázaro Cárdenas) thirds in another place, respectively; all places corresponded to the same municipality. Mares were kept in an extensive production system with nighttime confinement for rest. During grazing (9:00 a.m. to 6:00 p.m.), the animals consumed Buffel grass (*Cenchrus ciliaris* L./available year-round), and during confinement, they were supplemented with commercial total mixed ration (200 g/kg per animal). Clean water was provided *ad libitum*. Each mare was housed individually in 4 × 4 m stalls oriented north–south and equipped with shade structures, drinking troughs, and feed containers.

Experimental procedure

During the study period, the mares were kept under natural light conditions. To characterize follicular dynamics, all mares (non-lactating and non-pregnant) were evaluated throughout a complete oestrus cycle (~21 d, approximately) using real-time USG equipment (Kaixin KX-5200) equipped with a 6.5 MHz linear transducer. All follicles with an initial diameter of 8 mm were recorded and monitored daily until the ovulatory follicle reached approximately 45 mm in diameter. On the other hand, mares that had previously been covered by natural mating were included in the next phase of the study only if, after an evaluation performed 15 days post-mating, pregnancy was confirmed. Based on this confirmation, ultrasound monitoring of the presence of the embryonic sac and/or fetus was initiated and continued until 150 days of gestation. Finally, five ultrasound examinations were performed per mare during the study period.

Statistical analysis

Given the descriptive and observational nature of the study, the primary emphasis was placed on the visual characterization of follicular development and early gestation stages in mares through transrectal USG. While the dataset allows for potential quantitative analyses, this work was designed to provide morphological and visual benchmarks rather than to perform inferential statistics or hypothesis testing.

Data were analyzed using the FREQ and MEANS procedures of SAS (SAS 2004). Descriptive statistics were used to summarize the frequency and mean values of follicular diameters (≥8 mm) and the presence of embryonic or fetal structures at different gestational stages. Given the observational nature of the study, no inferential statistical tests were applied. Results were interpreted based on morphological consistency and visual identification criteria to establish practical ultrasonographic reference benchmarks for reproductive assessment under field conditions.

Results

As shown in Fig. 1, follicles were classified into three developmental groups according to diameter: early (8–20 mm), intermediate (21–30 mm), and preovulatory (32–45 mm). These accounted for 50.0%, 30.0%, and 20.0% of the total follicles observed, respectively. The mean number of follicles per mare was 5.0, reflecting typical cyclic activity under extensive tropical conditions.

Follicular dynamics

As shown in Fig. 1, follicles were classified into three developmental groups according to diameter: early (8–20 mm), intermediate (21–30 mm), and preovulatory (32–45 mm). These accounted for 50.0%, 30.0%, and 20.0% of the total follicles observed, respectively. The mean number of follicles per mare was 5.0, reflecting typical cyclic activity under extensive tropical conditions.

Follicular wall echogenicity and shape progressively changed as follicles approached ovulation, confirming their morphological differentiation as summarized in Table 1.

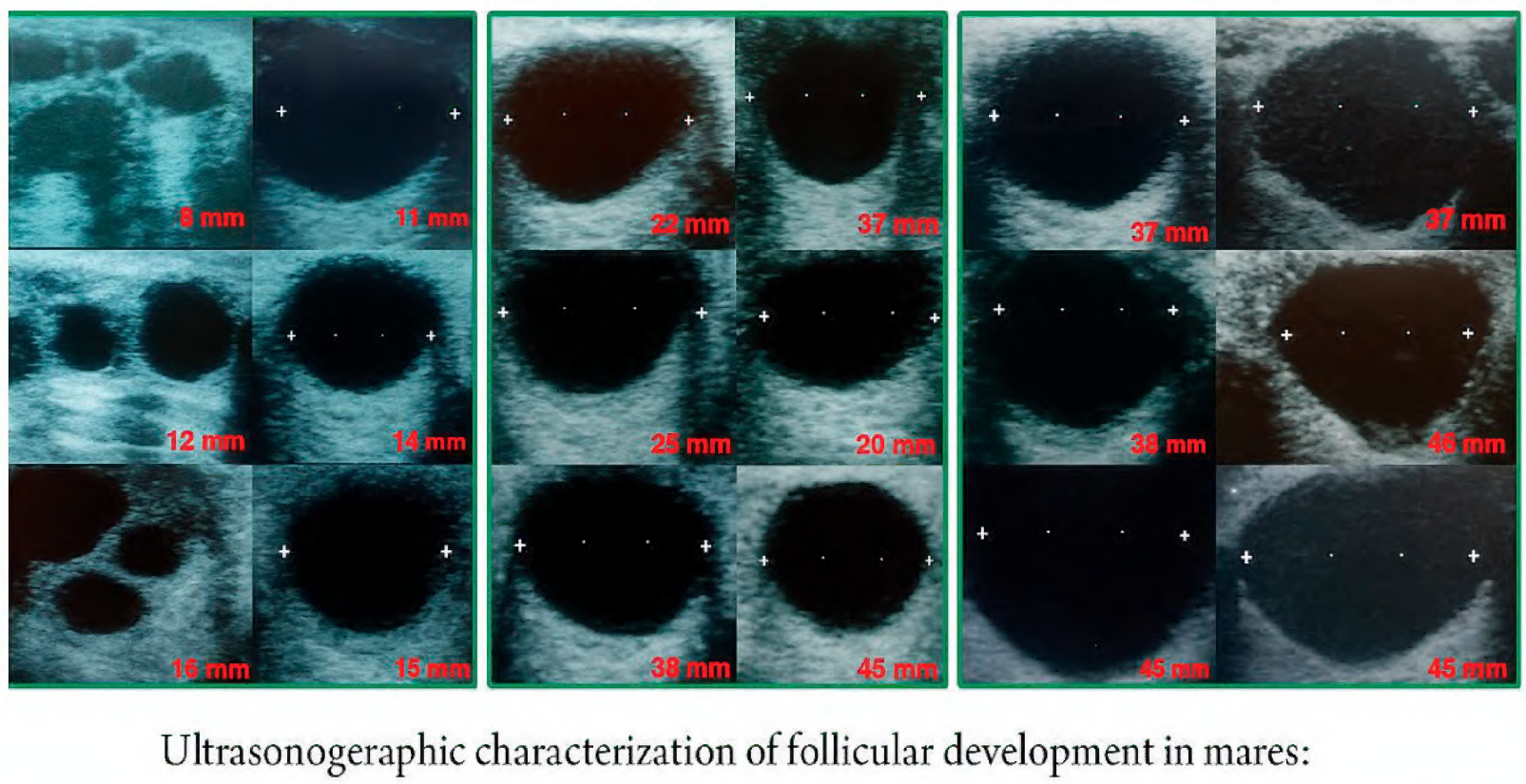

Ultrasonogeraphic characterization of follicular development in mares:

Figure 1. Ultrasonographic characterization of follicular development in mares. Representative transrectal ultrasonographic images showing the sequential stages of follicular growth: **A.** Small antral follicles (8–20 mm) with round, homogeneous, anechoic appearance; **B.** Intermediate follicles (21–30 mm) showing increased size and wall echogenicity consistent with deviation and selection of the dominant follicle; and **C.** Preovulatory follicles (32–45 mm) displaying thickened walls, loss of perfect sphericity, and localized apex brightening, indicative of imminent ovulation.

Table 1. Descriptive summary of follicular and gestational findings obtained by transrectal ultrasonography in mares under extensive field conditions.

Category	Group	Diameter / Gestational age (mean ± SD)	n	% of total	Main ultrasonographic features
Follicular development	A (Early)	13.7 ± 2.5 mm (range: 8–20 mm)	250	50	Small, round anechoic structures with homogeneous fluid content.
	B (Intermediate)	25.4 ± 2.1 mm (range: 21–30 mm)	150	30	Increasing echogenic wall; uniform antral cavity; early deviation phase.
	C (Preovulatory)	39.7 ± 2.9 mm (range: 32–45 mm)	100	20	Enlarged anechoic follicle with thickened wall; apex deformation indicating imminent ovulation.
Mean number of follicles per mare	-	-	5	-	Observed across one complete oestrus cycle per mare.
Gestational monitoring	A (Days 15–28)	21.9 ± 3.2 days	167	33.4	Embryonic vesicle visible; mobile, spherical, anechoic; fixation evident near day 16.
	B (Days 30–45)	38.8 ± 2.7 days	166	33.2	Embryo proper visible; heartbeat detected (~day 32); steady vesicle growth.
	C (Days 50–150)	75.1 ± 8.6 days	167	33.4	Fetal skeleton and movements observed; ossification from day 60–70.
Pregnancy outcomes	Confirmed pregnancies (day 15 post-mating)	-	100	100	Viable conceptus detected by ultrasound.
	Early embryonic losses (before day 45) *	-	Not observed	0	No embryonic mortality was recorded during monitoring.

*No cases of early embryonic death were detected within the monitored population.

Embryonic sac and/or fetus

The sequential development of the embryonic vesicle and fetus is illustrated in Fig. 2. Early gestational stages (days 15–28) were characterized by the presence of a mobile, spherical vesicle, while cardiac activity was first detected at approximately day 32 (days 30–45 group). From day 50 onward, fetal structures became progressively defined, with visible ossification of ribs and skull between days 60–70. The corresponding descriptive data are provided in Table 1, which consolidates the key visual milestones documented throughout early to mid-gestation.

Discussion

Follicular dynamics

Follicular development in mares is governed by coordinated endocrine, biochemical, and morphological mechanisms that reflect the cyclical nature of equine reproductive physiology. Transrectal USG has become a cornerstone in equine reproductive management, offering a non-invasive and field-adaptable method for real-time monitoring of follicular dynamics (Ginther et al. 2005). This technique enables the identification of follicular deviation, dominance, and preovulatory maturation, which

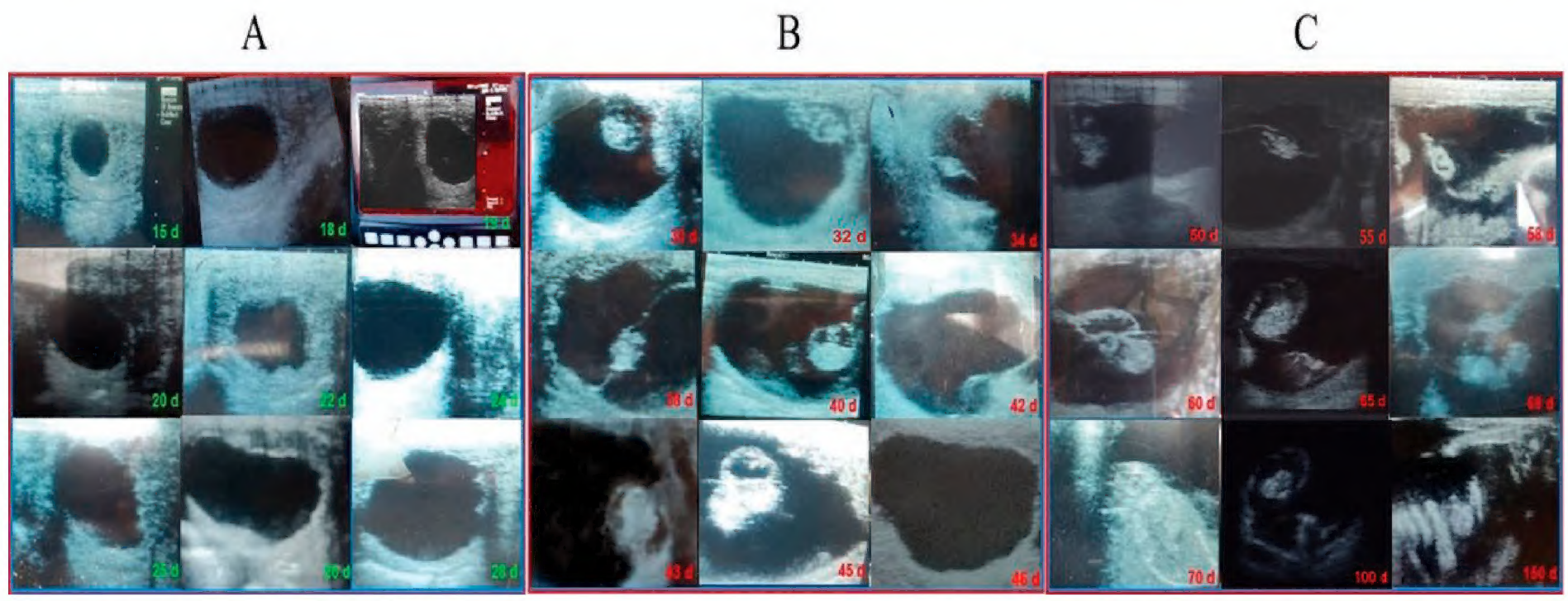

Figure 2. Ultrasonographic visualization of the embryonic sac and/or fetus in mares from day 15 to 150 of gestation. Representative images illustrating embryonic development stages: **A.** Days 15–28, showing a mobile, spherical embryonic vesicle with well-defined anechoic cavity and thin echogenic wall; **B.** Days 30–45, where the embryo proper and heartbeat become visible within the vesicle; and **C.** Days 50–150, showing the fetus with identifiable head, ribs, and vertebral column as echogenic structures surrounded by the amniotic fluid.

are essential for optimizing assisted reproductive strategies such as artificial insemination, embryo transfer, or ovulation induction (Silva et al. 2015; Fedorka et al. 2022). In extensively managed herds, where hormonal monitoring is often impractical, ultrasound provides a reliable proxy for assessing reproductive readiness. In our dataset, 50.0% of follicles were classified as early (8–20 mm), with a mean diameter of 13.7 mm. These values align with those reported by Duguma and Lemma (2020) in extensively managed local breeds and fall below the averages observed in Arabian and Thoroughbred mares under intensive reproductive programs, where preovulatory follicles often exceed 40 mm in diameter (Ginther et al. 2005; Arbal et al. 2015). This divergence supports the hypothesis that follicular dynamics may be modulated by extrinsic factors such as photoperiod, feed quality, and thermal stress, particularly in tropical systems (Das et al. 2023). Such findings reinforce the need for context-specific reproductive monitoring protocols, especially when applying assisted reproductive technologies in non-controlled environments.

The oestrus cycle in mares spans approximately 21 days and includes both a follicular phase—characterized by rising estrogen levels and follicle wave progression—and a luteal phase dominated by progesterone from the corpus luteum (Mocha et al. 2024). Follicular development is initiated by pulsatile GnRH secretion from the hypothalamus, which stimulates FSH release from the anterior pituitary, promoting antral follicle growth visible via transrectal USG (Aharonson-Raz 2012). In the common growth phase, follicles grow at a similar rate (~2–3 mm/day), with deviation occurring at a mean diameter of ~22.5 mm when the dominant follicle continues growing while subordinates regress (Ginther et al. 2002; Ginther et al. 2004).

During the early recruitment stage, we observed follicles of 8–20 mm in diameter in both ovaries, corresponding to primary selection mechanisms. Though most undergo atresia, one avoids apoptosis through upregulated FSH/LH receptors and increased expression of local survival factors such as IGF-1 and aromatase (Donadeu et al. 2014). These features manifest ultrasonographically as small, fluid-filled, anechoic structures—as shown in Fig. 1—confirming their healthy vascularization and growth status (Irvine and Alexander 1994; Korkmaz et al. 2021).

As follicles exceed 20 mm, they enter the deviation phase and transition into mid-follicular development (21–30 mm). This is associated with a sharp increase in estradiol, which negatively regulates FSH and primes the LH surge—mechanisms central to ovulation timing (Turna Yilmaz et al. 2015). Ultrasonographic markers such as maintained sphericity, fluid uniformity, and subtle changes in wall echogenicity and vascular flow, as identified by Doppler, reflect granulosa proliferation and neoangiogenesis mediated by vascular endothelial growth factor (VEGF) and other cytokines (Abdelnaby and Abo El-Maaty 2017).

Ultrasonographically, the dominant follicle retains its spherical shape and clear anechoic center while increasing in diameter, often showing subtle enhancements in wall echogenicity and vascular flow as detected by color Doppler imaging (Gastal et al. 2004; Abdelnaby and Abo El-Maaty 2017). These sonographic changes are indicative of granulosa cell proliferation and heightened angiogenesis at the follicular wall, mediated in part by elevated expression of VEGF (Dompe et al. 2021).

Follicles measuring 32–45 mm in diameter (Fig. 1) correspond to the preovulatory phase, typically occurring 24–48 hours before ovulation. At this stage, the luteinizing hormone (LH) surge triggers oocyte maturation and cumulus expansion. Simultaneously, structural modifications—such as follicular wall thickening, shape deformation (often pear-shaped), and localized increases in apex echogenicity—emerge as reliable sonographic predictors of imminent rupture (Korkmaz et al. 2021).

Biochemically, this phase is characterized by a sharp decline in estradiol levels and a rise in progesterone as granulosa cells luteinize post-ovulation. The follicular wall responds with the release of prostaglandins, matrix metalloproteinases, and inflammatory mediators necessary for follicular rupture and oocyte release into the oviduct (Riley et al. 2004).

The observation of follicles up to 45 mm aligns with data from Thoroughbred and Arabian mares, where preovulatory follicle diameters range between 35 and 45 mm (Arbal et al. 2015). Moreover, increases in wall heterogeneity and brightness (echotextural grayness values) have been validated by computer-assisted USG as auxiliary markers of follicular maturity and timing of ovulation, especially in purebred mares (Korkmaz et al. 2021).

USG therefore provides both morphological and functional insights into mare ovarian dynamics. This capability enables differentiation between physiological follicles and pathological entities such as hemorrhagic anovulatory follicles or luteinized unruptured follicles, conditions associated with altered anti-Müllerian hormone and estradiol profiles (Gharagozlou et al. 2014). Accurate tracking of follicular development—from 8 mm to 45 mm—through high-resolution imaging significantly narrows the window of error in breeding timing, thereby enhancing pregnancy rates in assisted reproduction programs (Riera 2009).

Embryonic sac and/or fetus

USG has revolutionized equine reproductive management by offering real-time, non-invasive visualization of the developing embryo and fetus. Its diagnostic value extends beyond simple pregnancy detection, encompassing fetal viability assessment, developmental staging, and the identification of abnormalities. As equine breeding programs adopt increasingly advanced assisted reproductive technologies, precise timing and understanding of gestational milestones have become essential. This work presents an integrative analysis of ultrasonographic data from 100 mares examined longitudinally from day 15 to day 150 post-breeding, with particular focus on embryonic and fetal morphology, endocrine signaling, and environmental variability.

Mare gestation is hormonally and metabolically orchestrated through tightly regulated pathways. Progesterone plays a central role in early pregnancy maintenance, with corpus luteum-derived progesterone sustaining the uterine environment until placental structures take over steroidogenic support. The maternal recognition of pregnancy, occurring around day 16 post-ovulation, is crucial for luteostasis and is facilitated by suppression of prostaglandin F2α (PGF2α) secretion from the endometrium, mediated by conceptus-derived signals (Allen 2018). Concomitantly, embryonic vesicle fixation at this stage marks a physiological turning point, initiating a cascade of placental and embryonic development.

From a biochemical standpoint, early embryonic development is characterized by rapid cellular proliferation and the onset of organogenesis. IGF-1, VEGF, and aromatase activity are involved in regulating trophoblastic expansion and vascularization. In our cohort, the embryonic vesicle was visible via transrectal USG by day 15 in nearly all mares, appearing as a mobile, spherical anechoic structure with an average diameter of 5.3 mm. Growth rates of 3.2 ± 0.4 mm/day were consistent with previous findings by (McKinnon et al. 2011), who emphasized that early vesicle expansion is predictive of successful implantation and fixation (Squires et al. 1988).

However, vesicle mobility and growth patterns varied by breed and management system. Mares managed under intensive reproductive programs (e.g., Warmbloods and Arabians) showed more uniform fixation patterns and earlier transitions to embryonic visibility compared to extensively managed local breeds. These findings support reports by Hendriks et al. (2009), who demonstrated that parity and maternal age influence fetal measurements, with primiparous mares often exhibiting thicker uteroplacental interfaces. Similarly, in tropical climates, environmental stressors such as heat and suboptimal nutrition may delay fixation and compromise vesicle growth, consistent with the work of Faitma et al. (2023).

By days 30–45, embryonic differentiation is marked ultrasonographically by the presence of the embryo proper within the vesicle and the onset of cardiac activity. We observed echogenic embryonic poles in over 93% of mares during this period, with a pulsatile flicker indicating viable cardiac function by day 32. These findings are aligned with (Renaudin et al. 1997), who reported cardiac detection in over 90% of pregnancies by day 30.

Endocrinologically, this stage coincides with the formation of endometrial cups and the secretion of equine chorionic gonadotropin (eCG), a critical factor for luteal support and progesterone maintenance. Although hormonal assays were not conducted in this study, the ultrasonographic identification of consistent embryonic cardiac activity and growth strongly implies functional endocrine support. Studies in Dutch Warmblood mares show that CTUP (combined thickness of uterus and placenta) correlates with eCG activity and can be used to predict placental health (Renaudin et al. 1997).

In the mid-gestational phase (days 50–150), structural differentiation becomes more evident. Ossified skeletal elements such as ribs, skull, and vertebrae became detectable by day 70 in 87% of our sample, and in some mares as early as day 60. This matches observations by (Renaudin et al. 2024) who noted ossification onset between days 60–80 in Warmblood and Shetland mares, respectively (Wagner et al. 2024).

Importantly, some mares under extensive tropical management showed delayed ossification until day 100, which may reflect slower fetal mineralization due to nutritional insufficiencies or thermoregulatory strain.

Fetal movement increased from day 80 onward, accompanied by asymmetry in limb and trunk development. These dynamics reflect maturing neuromuscular coordination and central nervous system integrity. Late gestational ultrasound studies, such as those by González et al. (2025), have shown that fetal eye measurements and biometric data can predict parturition with high precision, underscoring the potential of extended ultrasonographic monitoring.

Our findings also affirm the value of breed-specific reference ranges. For example, crossbred and local mares demonstrated greater variability in vesicle size and ossification timelines than their intensively managed counterparts. This is consistent with research by Pipers et al. (1984), who documented breed-dependent differences in embryonic growth curves. In turn, such variability justifies the need for contextual reproductive protocols that consider environmental and genetic influences.

Clinically, the implications of our timeline are multifaceted. Early gestational detection (days 15–25) allows accurate identification of pregnant versus non-pregnant mares, facilitating timely rebreeding. Intermediate confirmation (days 30–45) of cardiac activity serves as a proxy for embryonic viability and luteal sufficiency. Mid-gestational imaging (days 50–150) enables structural surveillance, the detection of placental abnormalities (e.g., placentitis), and the evaluation of fetal growth trajectories.

Conclusions

This study underscores the scientific and clinical value of transrectal ultrasonography as a reliable, non-invasive, and field-adapted diagnostic tool for evaluating both follicular dynamics and early gestation in mares. By establishing visual benchmarks and quantitative references under extensive management conditions, it bridges the gap between controlled reproductive research and practical equine herd management. The ultrasonographic profiles documented herein provide a valuable framework for veterinary education, clinical decision-making, and breeding optimization. Routine application of these visual references is recommended to improve reproductive assessment accuracy and facilitate early pregnancy monitoring in field-based equine production systems.

Conflict of interest

There are no known conflicts of interest associated with this publication and there has been no significant financial support for this work that could have influenced its outcome.

Author contributions

Conceived the experiment: Quintero-Elisea Juan Alberto, and Hernández-Rivera Juan Augusto. Performed field trial: Velázquez-Morales José Vicente, Olguin-Arredondo Hector Armando and Prado-Rebolledo Omar Francisco. Performed statistical analysis and interpretation of results: García-Casillas Arturo César. Wrote the manuscript: Quintero-Elisea Juan Alberto, and Hernández-Rivera Juan Augusto. All authors read and approved the manuscript.

Ethical statement

This study was conducted in accordance with approved local animal care guidelines, specifically the Mexican Official Standard NOM-051-ZOO-1995 for the humanitarian treatment of animals during mobilization.

References

Abdelnaby EA, Abo El-Maaty AM (2017) Dynamics of follicular blood flow, antrum growth, and angiogenic mediators in mares from deviation to ovulation. Journal of Equine Veterinary Science 55: 51–59. https://doi.org/10.1016/j.jevs.2017.04.003

Aharonson-Raz K (2012) Ovarian follicular dynamics during the estrous cycle in the mare. Israel Journal of Veterinary Medicine 67: 11–18. https://ijvm.org.il/sites/default/files/ovarian_follicular_dynamics_of_the_mare.pdf [Google Scholar]

Allen W (2005) Maternal recognition and maintenance of pregnancy in the mare. Animal Reproduction 2: 209–223. https://host-article-assets.s3.amazonaws.com/animreprod/5b5a6088f7783717068b47fe/fulltext.pdf [Google Scholar]

Arbal R, Ingawale M, Deshmukh S, Hajare S (2015) Studies on embryonic development in thoroughbred mares. The Indian Journal of Veterinary Sciences and Biotechnology 11: 11–14. [Google Scholar]

Benammar A, Derisoud E, Vialard F, Palmer E, Ayoubi JM, Poulain M, Chavatte-Palmer P (2021) The mare: a pertinent model for human assisted reproductive technologies? Animals 11: 2304. https://doi.org/10.3390/ani11082304

Cabeza JP, Gambini A (2023) Advancements and challenges in in vitro reproductive technologies for the conservation of equine species. Theriogenology Wild 2: 100036. https://doi.org/10.1016/j.therwi.2023.100036

Das PK, Mukherjee J, Banerjee D (2023) Female Reproductive Physiology. In: Das PK, Sejian V, Mukherjee J, Banerjee D (Eds) Textbook of Veterinary Physiology. Springer Nature Singapore, Singapore, 513–568. https://doi.org/10.1007/978-981-19-9410-4_22

Dompe C, Kulus M, Stefańska K, Kranc W, Chermuła B, Bryl R, Pieńkowski W, Nawrocki MJ, Petitte JN, Stelmach B, Mozdziak P, Jeseta M, Pawelczyk L, Jaśkowski JM, Piotrowska-Kempisty H, Spaczyński RZ, Nowicki M, Kempisty B (2021) Human granulosa cells—stemness properties, molecular cross-talk and follicular angiogenesis. Cells 10: 1396. https://doi.org/10.3390/cells10061396

Donadeu FX, Fahiminiya S, Esteves CL, Nadaf J, Miedzinska K, McNeilly AS, Waddington D, Gérard N (2014) Transcriptome profiling of granulosa and theca cells during dominant follicle development in the horse. Biology of Reproduction 91: 1–12. https://doi.org/10.1095/biolreprod.114.118943

Duguma A, Lemma A (2020) Ovarian follicular dynamics and uterine changes during the ovulatory wave predicts imminent ovulation in Mares. International Journal of Veterinary Science and Research 6: 041–046. https://doi.org/https://dx.doi.org/10.17352/ijvsr.000052

Faitma A, Ahsan Z, Nasir O, Bilal RM, Junaid M, Sadar M, Younas U (2023) Biological attributes of livestock as affected by heat stress in tropical and sub-tropical regions. Current Studies in Health Life Sciences 1: 408–443. [Google Scholar]

Fedorka CE, El-Sheikh Ali H, Scoggin KE, Loux SC, Ball BA, Troedsson MHT (2022) Tumor necrosis factor signaling during equine placental infection leads to pro-apoptotic and necroptotic outcomes. Journal of Reproductive Immunology 152: 103655. https://doi.org/10.1016/j.jri.2022.103655

Gastal EL, Gastal MO, Beg MA, Ginther OJ (2004) Interrelationships among follicles during the common-growth phase of a follicular wave and capacity of individual follicles for dominance in mares. Reproduction 128: 417–422. https://doi.org/10.1530/rep.1.00259

Gharagozlou F, Akbarinejad V, Youssefi R, Masoudifard M, Hasani N (2014) Reduced anti-Müllerian hormone (AMH) in mares with hemorrhagic anovulatory follicles. Iranian Journal of Veterinary Research 15: 336–340. https://doi.org/10.22099/ijvr.2014.2588

Ginther OJ, Gastal EL, Gastal MO, Beg MA (2005) Regulation of circulating gonadotropins by the negative effects of ovarian hormones in mares. Biology of Reproduction 73: 315–323. https://doi.org/10.1095/biolreprod.105.040253

Ginther OJ, Gastal EL, Gastal MO, Bergfelt DR, Baerwald AR, Pierson RA (2004) Comparative study of the dynamics of follicular waves in mares and women. Biology of Reproduction 71: 1195–1201. https://doi.org/10.1095/biolreprod.104.031054

Ginther OJ, Meira C, Beg MA, Bergfelt DR (2002) Follicle and endocrine dynamics during experimental follicle deviation in mares. Biology of Reproduction 67: 862–867. https://doi.org/10.1095/biolreprod.102.004309

González SW, Espy BMK, Stefanovski D, Turner RM (2025) Real-time transrectal ultrasonographic measurement of the fetal eye (vitreous body) to predict parturition in bucking horse mares. Journal of Equine Veterinary Science 145: 105345. https://doi.org/10.1016/j.jevs.2025.105345

Hendriks WK, Colenbrander B, van der Weijden GC, Stout TAE (2009) Maternal age and parity influence ultrasonographic measurements of fetal growth in Dutch Warmblood mares. Animal Reproduction Science 115: 110–123. https://doi.org/10.1016/j.anireprosci.2008.12.014

INEGI (2025) Cuéntame de México. Sección educativa. Tamaulipas. 2025. [cited 2025; Available from] https://cuentame.inegi.org.mx/descubre/conoce_tu_estado/tarjeta.html?estado=28

Irvine CHG, Alexander SL (1994) The dynamics of gonadotrophin-releasing hormone, LH and FSH secretion during the spontaneous ovulatory surge of the mare as revealed by intensive sampling of pituitary venous blood. Journal of Endocrinology 140: 283–295. https://doi.org/10.1677/joe.0.1400283

Khan IU, Khairullah AR, Khan AY, Rehman AU, Mustofa I (2025) Strategic approaches to improve equine breeding and stud farm outcomes. Vet World 18: 311–328. https://doi.org/10.14202/vetworld.2025.311-328

Korkmaz Ö, Akkuş T, Emre B, Zonturlu AK (2021) The relationship between digital ultrasonographic image echotexture parameters of the uterus and preovulatory follicle development and ovulation in purebred Arabian mares. Veterinarski Arhiv 91: 261–268. https://hrcak.srce.hr/clanak/378284

Lange-Consiglio A, Gaspari G, Funghi F, Capra E, Cretich M, Frigerio R, Bosi G, Cremonesi F (2023) Amniotic mesenchymal-derived extracellular vesicles and their role in the prevention of persistent post-breeding induced endometritis. International Journal of Molecular Sciences 24: 5166. https://doi.org/10.3390/ijms24065166

Lowe G, McCane B, Sutherland M, Waas J, Schaefer A, Cox N, Stewart M (2020) Automated collection and analysis of infrared thermograms for measuring eye and cheek temperatures in calves. Animals 10: 292. https://doi.org/10.3390/ani10020292

McKinnon AO, Squires EL, Vaala WE, Varner DD (2011) Equine reproduction. John Wiley & Sons. [Google Scholar]

Mocha SGS, Inga EGY, Herrera CAM (2024) Endocrinología reproductiva en yeguas, una revisión. RECIENA 4: 6–11. https://doi.org/10.47187/gwqq4n57

Ortega-Ferrusola C, Gómez-Arrones V, Martín-Cano FE, Gil MC, Peña FJ, Gaitskell-Phillips G, Da Silva-Álvarez E (2022) Advances in the ultrasound diagnosis in equine reproductive medicine: New approaches. Reproduction in Domestic Animal 57: 34–44. https://doi.org/10.1111/rda.14192

Panzani D, Cuervo-Arango J, Fanelli D (2024) Ultrasonographic pregnancy diagnosis in the mare. In: Gardón JC, Satué Ambrojo K (Eds) Assisted reproductive technologies in animals volume 1: current trends for reproductive management. Springer Nature Switzerland, Cham, 29–47. https://doi.org/10.1007/978-3-031-73079-5_2

Pipers FS, Zent W, Holder R, Asbury A (1984) Ultrasonography as an adjunct to pregnancy assessments in the mare. Journal of the American Veterinary Medical Association 184: 328–334. https://doi.org/10.2460/javma.1984.184.03.328

Renaudin C, Troedsson M, Gillis C, King V, Bodena AJT (1997) Ultrasonographic evaluation of the equine placenta by transrectal and transabdominal approach in the normal pregnant mare. Theriogenology 47: 559–573. https://doi.org/10.1016/S0093-691X(97)00014-9

Renaudin C, Wensley F, Morgan J, Cassano J, Spriet M (2024) Transrectal ultrasonographic assessment of the fetal proximal phalanx: A new tool to assess fetal age and bone development in horses. Theriogenology 226: 167–172. https://doi.org/10.1016/j.theriogenology.2024.06.010

Riera FL (2009) Chapter 16 - Equine Embryo Transfer. In: Samper JC (Ed.) Equine breeding management and artificial insemination (second edition). W.B. Saunders, Saint Louis, 185–199. https://doi.org/10.1016/B978-1-4160-5234-0.00016-7

Riley SC, Thomassen R, Bae S-E, Leask R, Pedersen HG, Watson ED (2004) Matrix metalloproteinase-2 and -9 secretion by the equine ovary during follicular growth and prior to ovulation. Animal Reproduction Science 81: 329–339. https://doi.org/10.1016/j.anireprosci.2003.10.011

SAS (2004) SAS/STATU ser's Guide Software Released. SAS Institute Inc: Cary, NC, USA.

Silva ESAMd, Pantoja JCdF, Puoli Filho JNP, Meira C (2015) Ultrasonography of the conceptus development from days 15 to 60 of pregnancy in non-cyclic recipient mares. Ciência Rural 45: 512–518. https://doi.org/10.1590/0103-8478cr20140517

Squires EL, McKinnon AO, Shideler RK (1988) Use of ultrasonography in reproductive management of mares. Theriogenology 29: 55–70. https://doi.org/10.1016/0093-691X(88)90031-3

Turna Yilmaz Ö, Toydemir TSF, Kirsan I, Gunay Ucmak Z, Caliskan Karacam E (2015) Anti-Müllerian hormone as a diagnostic tool for ovarian remnant syndrome in bitches. Veterinary Research Communications 39: 159–162. https://doi.org/10.1007/s11259-015-9639-0

Wagner L-H, Aurich J, Claaßen S, Melchert M, Kaps M, Aurich C (2024) Assessment of fetal development during mid and late term pregnancies by standard B-Mode ultrasonography in Shetland ponies. Journal of Equine Veterinary Science 141: 105162. https://doi.org/10.1016/j.jevs.2024.105162